



## Fahr's syndrome and idiopathic hypoparathyroidism – A case report

### Farov sindrom i idiopatski hipoparatiroidizam

Dejan M. Marinković\*, Tamara Dragović\*<sup>†</sup>, Saša Kiković\*,  
Snežana Kuzmić Janković\*, Zorana Djuran\*, Zoran Hajduković\*<sup>†</sup>

\*Clinic for Endocrinology, Military Medical Academy, Belgrade, Serbia; <sup>†</sup>Faculty of  
Medicine of the Military Medical Academy, University of Defence, Belgrade, Serbia

#### Abstract

**Introduction.** Fahr's syndrome is a rare, slowly progressive, neurodegenerative disorder, characterised by extensive, bilateral, and symmetrical basal ganglia calcification. It is associated with neuropsychiatric manifestations and gradually progressive cognitive impairment. Fahr's syndrome is the secondary form of brain calcification that is caused by various metabolic, infectious, or degenerative diseases. **Case report.** We presented a middle-aged male with Fahr's syndrome due to primary idiopathic hypoparathyroidism. Clinical diagnosis was based on signs and symptoms of hypocalcemia, progressive neuropsychiatric illnesses, laboratory evidence of hypoparathyroidism, and radiological signs of calcifications in the basal ganglia. The patient improved after only a few days of intravenous rehydration and calcium substitution, followed by oral supplemental calcitriol. **Conclusion.** Timely recognition of idiopathic and iatrogenic hypoparathyroidism allows appropriate treatment that can prevent the development and clinical manifestations of Fahr's syndrome and potentially slow its progression.

#### Key words:

neurodegenerative diseases; calcinosis; basal ganglia; hypoparathyroidism; comorbidity; diagnosis; differential; drug therapy.

#### Apstrakt

**Uvod.** Farov sindrom je retko, sporonapredujuće, neurodegenerativno oboljenje sa tipično obostranim i simetričnim kalcifikacijama bazalnih ganglija, koje se najčešće manifestuje neuropsihijatrijskim tegobama sa progresivnim oštećenjem kognitivnih funkcija. Farov sindrom je sekundarni oblik kalcifikacija mozga uzrokovanih raznim metaboličkim, infektivnim ili degenerativnim oboljenjem. **Prikaz bolesnika.** Prikazan je sredovečni bolesnik sa Farovim sindromom uzrokovanim idiopatskim hipoparatiroidizmom. Dijagnoza je postavljena na osnovu progresivnih neuropsihijatrijskih tegoba, laboratorijskih pokazatelja hipokalcemije i hipoparatiroidizma, kao i radiološkog nalaza simetričnih, bilateralnih kalcifikacija, pre svega bazalnih ganglija. Stanje bolesnika bitno je popravljeno i stabilizovano nakon samo nekoliko dana parenteralne-intravenske nadoknade kalcijuma, rehidracije i primene oralnih preparata calcitriola. **Zaključak.** Blagovremeno prepoznavanje i lečenje idiopatskog ili jatrogenog hipoparatiroidizma ostavlja mogućnost sprečavanja nastanka, kliničke manifestacije ili bar progresije Farovog sindroma, tj. kalcifikacija bazalnih ganglija.

#### Ključne reči:

neurodegenerativne bolesti; kalcinoza; bazalne ganglije; hipoparatiroidizam; komorbiditet; dijagnoza, diferencijalna; lečenje lekovima.

#### Introduction

Fahr's syndrome (FS) is a rare, chronic, slowly progressive, neurodegenerative disorder characterised by extensive bilateral, and symmetrical deposition of calcium in the basal ganglia, thalamus, cerebral cortex, dentate nucleus, cerebellum subcortical white matter, and hippocampus<sup>1-3</sup>. Clinical manifestations occur typically in the fourth or fifth decade of age and usually includes neuropsychiatric manifestations with gradually progressive cognitive impairment<sup>2,4</sup>. The on-

set of the disease is usually insidious and frequently is misdiagnosed as a dementia or psychiatric illness.

Hypoparathyroidism (HP) is an endocrine disorder, caused by a heterogeneous group of conditions, in which low calcium and high phosphate levels occur as the result of insufficient parathyroid hormone (PTH) secretion. Idiopathic hypoparathyroidism is a term for a rare deficient PTH secretion without definitive cause and may be genetically inherited or may have an autoimmune cause. Radiologically, this state may cause calcifications, predominantly in *globus pal-*

*lidus* of the basal ganglia. Symptoms attributable to their involvement are uncommon at the clinical presentation<sup>5-7</sup>.

Histological findings in the form of symmetrical brain calcifications, were observed for the first time by Bomberger in 1855<sup>8</sup>. Clinical manifestations of Fahr's syndrome was first described in 1930 by German neurologist Karl Theodor Fahr<sup>1, 3, 4, 9</sup>. The association of basal ganglia calcifications with chronic HP, was described for the first time by Eaton et al.<sup>10</sup> in 1939.

Today, there are two entities associated with basal ganglia calcification. The primary form, also called Fahr's disease, is characterised by idiopathic calcifications of brain tissue and it is considered as familial or sporadic disorder. Fahr's syndrome is the secondary form of brain calcifications, that is caused by some other known disease<sup>3, 4, 9, 11, 12</sup>.

We presented a middle-aged male with Fahr's syndrome caused by the primary idiopathic hypoparathyroidism.

### Case report

A 58-year-old male admitted to our clinic for the history of polymorphic complaints in the form of general weakness, headache, middle back pain, retrosternal chest, and diffuse abdominal pain over the 2-month period. He also had an intermittent episodes of generalised muscle cramps, numbness, tingling, fever, and diarrhea, followed with a mark reduction in body weight. The members of his family noticed some changes in overall behaviour like periodical irritability or disorientation. All of the symptoms occurred suddenly two months ago, after upper respiratory tract infection, and were getting worse in the last few days. Physical examination revealed ataxia, bradypsychic response, adynamia, asthenic constitution, edentulousness, slurred speech, mental confusion, and positive Trousseau sign of latent tetany. He had body temperature of 37.5°C, pale skin with

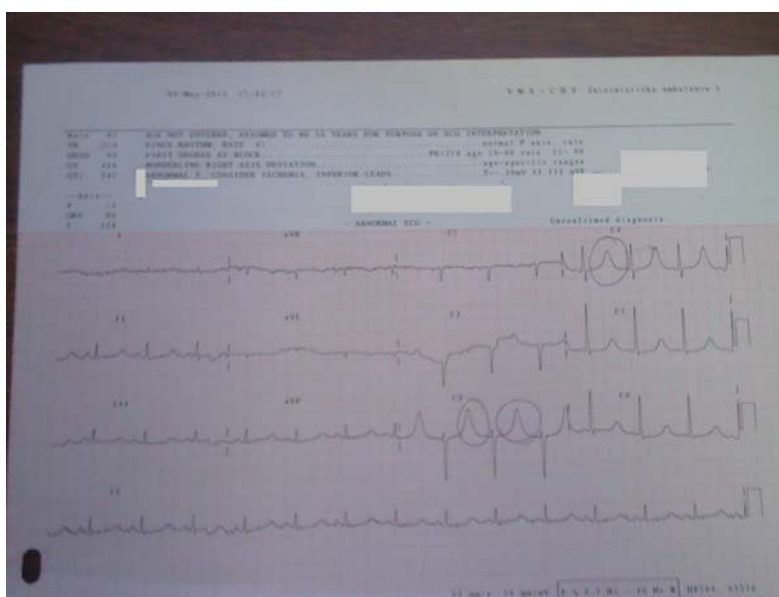
no edema or skin lesion. His blood pressure was 100/60 mmHg, with puls rate of 100 beats *per* minute with no organomegaly or lymphadenopathy. The rest of physical examination was unremarkable.

Electrocardiogram revealed episodes of sinus tachycardia with first degree atrioventricular block and slow and prolonged depolarisation (PR interval 214, QT interval over 466 ms) (Figure 1).

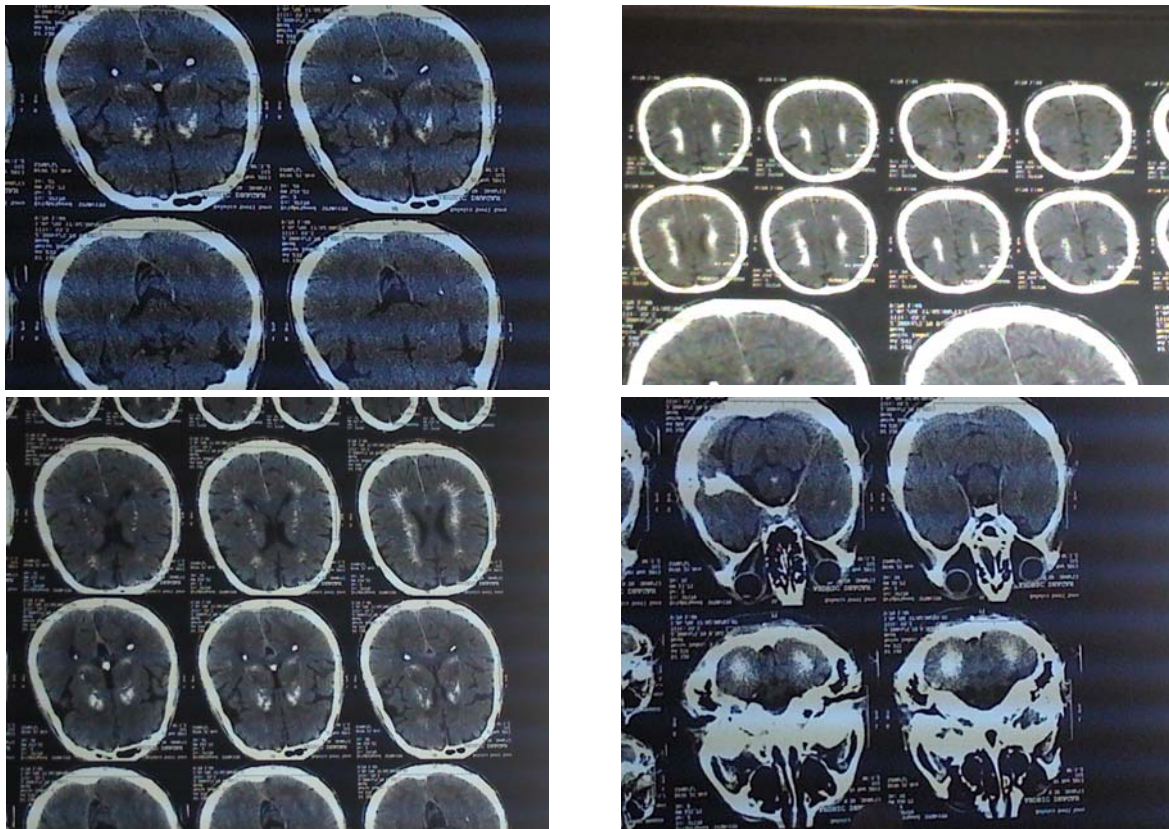
Laboratory blood tests showed elevated inflammatory biomarkers: erythrocyte sedimentation rate of 63 mm *per* hour and C-reactive protein level of 36 mg/L (normal range 0.00–3.00 mg/L), normocytic anaemia with haemoglobin value of 109 g/L (normal value 130–180 g/L) and positive urine tests for urinary infection. Biochemistry results included normal concentrations of serum albumin, glucose, bilirubin, cholesterol, potassium, sodium, and serum liver enzyme levels. Serum calcium levels were decreased up to 0.97 mmol/L (normal range 2.13–2.63 mmol/L), ionized calcium level of 0.70 mmol/L (normal range 1.00–1.30 mmol/L) and parathyroid hormone level of 0.44 pmol/L (normal range 1.59–6.89 pmol/L) were also decreased. Serum phosphorus level of 2.00 mmol/L was higher than normal range (0.78–1.65 mmol/L). The results of all other hormone tests were normal.

Multislice computer tomography (CT) of the brain revealed multiple symmetrical large areas of calcification in the basal ganglia, periventricular, supraventricular white matter, as well as in the central regia of pons (Figure 2).

With the exception of hypocalcemia and HP, other secondary causes of brain calcifications were excluded by laboratory testing. Chest radiography and ultrasound examination of the neck, abdomen and pelvis were normal. Osteodensitometry revealed normal bone density. Endoscopic examination of the upper intestine was normal. The ophthalmologist did not see signs of papilledema.



**Fig. 1 – Electrocardiogram of a patient with Fahr's syndrome showing first degree atrioventricular block and slow and prolonged depolarisation (PR interval 214 ms, QT interval over 466 ms).**



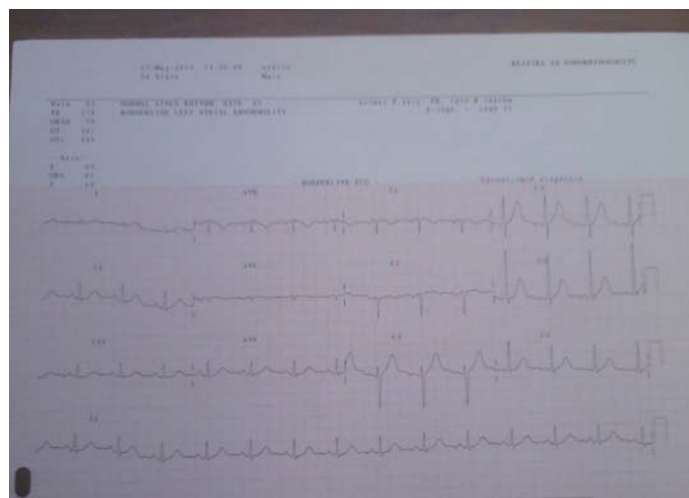
**Fig. 2 – Brain computed tomography (CT) scan revealing bilateral, multiple, symmetric calcifications in the basal ganglia, periventricular and supraventricular, also infratentorial in the cerebellum and pons centrally.**

On the basis of clinico-radiological and biochemical findings, diagnosis of primary HP and Fahr's syndrome was suggested.

Immediately after admission to the clinic, the patient got intravenous rehydration, antibiotics and calcium infusion, followed by oral supplemental calcium and calcitriol. Parenteral anticoagulation therapy was also conducted, while thiazide diuretics were administered in order to diminish calciuria. Dominant

neuropsychiatric signs were stopped by mild anxiolytic therapy.

Gradually after two weeks, all laboratory tests, clinical signs, and electrocardiogram finding went back to normal (Figure 3). He was recommended to take lifelong calcium and calcitriol substitution. Ambulatory, a 6-month control, evidenced maintaining of good general condition without any neurological symptoms or mental disorder. Serum calcium and ionized calcium levels were held at the lower reference limits.



**Fig. 3 – Control electrocardiogram evidencing normalization of the duration of electrical systole and out of the first degree atrioventricular block.**

## Discussion

Basal ganglia calcification (BGC) is a nonspecific finding in 1% of radiographic brain examination<sup>13, 14</sup>. These calcifications could be conditionally separated in two main forms: primary and secondary<sup>3</sup>.

The term Fahr's disease refers to cases of idiopathic calcifications in the basal ganglia and other brain regions, and is clinically defined as bilateral BGC in the presence of neuropsychiatric and extrapyramidal disorders with normal calcium and parathyroid levels<sup>4, 12</sup>. Fahr's disease could be sporadic or inherited in an autosomal dominant pattern with the commonly involved locus at 14 q chromosome. Some form of this disease may also be passed on as an autosomal recessive trait<sup>1, 4, 5, 15, 16</sup>. This disease is also known as familial idiopathic basal ganglia calcifications; still there are 35 additional terms used for this condition in the literature. Some synonyms for this disease are: idiopathic striopallidodentate calcinosis, cerebrovascular ferro calcinosis, calcinosis nucleorum, familial idiopathic cerebral calcifications etc.<sup>3, 9</sup>.

In contrast to this primary form, bilateral and symmetric calcifications of basal ganglia and other brain regions, can occur secondary, as the consequence of various metabolic, infectious, or degenerative disease. These includes endocrine disorders, mitochondrial myopathy, some dermatological disorders, brucellosis, toxoplasmosis, etc.<sup>3, 4, 13</sup>. This condition is known as Fahr's syndrome. Clinically, it should be clearly distinguished from Fahr's disease<sup>3</sup>.

Therefore, common for both conditions are bilateral BGC and progressive neuropsychiatric manifestations. The essential difference between the disease and the syndrome is the presence of the family history of BGC (Fahr's disease) and evidence of some other, known cause (Fahr's syndrome).

The most common reported metabolic disorders that cause Fahr's syndrome are HP and pseudohypoparathyroidism<sup>1, 17</sup>. HP could be iatrogenic, as the consequence of surgical removal or radiotherapy, or could be idiopathic<sup>1, 6, 13</sup>. The latter refers to deficient PTH secretion without a defined cause and includes a group of rare conditions that can be genetically inherited and/or autoimmune. Inherited genetic HP may run in families by passing on with autosomal dominant, autosomal recessive or X-linked pattern, and may occur in childhood or later in life. Autoimmune HP may be isolated, or exist as a part of polyglandular syndrome such as autoimmune polyglandular syndrome type 1 or type 2. The former disorder is also inherited, but it usually occurs until the period of early adolescence and always by the age of 25. The latter presents in adulthood in combination with adrenal insufficiency, type 1 diabetes mellitus, or thyroid autoimmune diseases<sup>5-7, 13, 18</sup>. The most common cause of HP is damage or removal of the parathyroid glands during thyroidectomy<sup>19, 20</sup>. In postoperative HP, basal ganglia calcifications will develop in untreated patients, after a median of 17 years<sup>13, 21</sup>. Early treatment of postoperative HP can prevent brain calcifications with typical manifestations<sup>6, 10</sup>. In patients with idiopathic form of HP, adequate oral calcitriol and calcium supplementation is

needed in order to restore calcium/phosphorus ratio and reduce the risk of basal ganglia calcification appearance and progression<sup>6, 13, 22</sup>.

There is no clear explanation for the mechanism of brain calcification and hypocalcemia association. It is suggested that increased calcium-phosphorus complex formation plays an important role<sup>6, 13</sup>. It is possible that the subsidence of calcium in the brain parenchyma, appear due to local disruption of the blood-brain barrier or due to a disorder of neuronal calcium metabolism. Active role of PTH in the basal ganglia physiology could also be involved. There are some findings that psychiatric conditions may be associated with calcium dysregulation, calcium signaling and altered calcium homeostasis<sup>3, 4</sup>. Histological examination of affected areas revealed concentric calcium deposits within small and medium-sized arterial walls as well as droplet calcifications along capillaries<sup>6</sup>.

The most common clinical features are neurological as seizures, spasticity, choreoathetosis, tremor, headache, vertigo, dysarthria, loss of consciousness. Psychiatric features include depression, manic symptoms, irritability, aggression, or deterioration of intelligence<sup>1, 3, 4, 16, 18</sup>. The impact of changes in calcium levels in the QT interval in ECG recording is well-known. In our case, electrocardiogram revealed episodes of sinus tachycardia with first degree AV block and prolonged depolarisation, fully retreated with normal serum calcium levels. Cardiac conduction disease were also observed in some cases of FD<sup>23</sup>.

In contrast to typical slowly progressive neuropsychiatric manifestations, in our case, all of the neurological symptoms occurred suddenly, and were provoked by respiratory infection. Polymorphic symptoms, including diffuse cramps, diarrhea, and body pain were non specific, while mental disorientation and irritability were noticed only periodically. Other neurological manifestations, such as ataxia, adynamia, slurred speech, and mental confusion progressed rapidly in a few days. All of the symptoms related to hypocalcemia occurred in a short, 2-month interval, with no accompanied endocrine disorder, suggesting isolated idiopathic HP. Still, these symptoms were also the most prominent feature of clinical presentation in our patient, with positive Trousseau sign, decreased serum calcium, and PTH levels, followed by typical prolonged QT interval on electrocardiographic (ECG) examination. CT finding of bilateral brain calcifications completed the diagnosis towards Fahr's syndrome due to HP.

To date, there is no standard course of treatment for Fahr's syndrome/disease. A recent prospective study has found that increased risk for BGC progression is significantly associated with low calcium/phosphorus ratio, hyperphosphatemia and history of seizures<sup>6, 13</sup>. Nevertheless, serum levels of 25(OH)D vitamin and 1.25 (OH)2D vitamin were not significantly associated with progression. Interestingly, with every 1% increase in the calcium/phosphorus ratio, progression of basal ganglia calcification decreased by 5%<sup>6, 13, 19</sup>.

Recommended treatment is directed toward symptomatic control of neurological manifestations using anxiolytics, antipsychotics, anticonvulsant treatment with appropriate rehydration, electrolyte, and hemodynamic balance maintenance<sup>4, 8, 18</sup>. In cases of Fahr's syndrome due to hypoparathyroidism, the neurological and psychiatric

symptoms usually improve with normalisation of plasma calcium and phosphorus levels. It is recommended to obtain a target serum calcium level in the low normal range<sup>6, 12</sup>. HP is a rare endocrine condition with a hormone deficiency, that does not necessarily require the same substitution<sup>18</sup>. The subcutaneous application of synthetic PTH analogs are recommended only in refractory forms with chronic hypercalciuria and kidney complications<sup>5, 7, 13, 24, 25</sup>.

The presented patient showed no need for serious anti-convulsant or antipsychotic treatment. Dramatic clinical presentation and difficult general state of the presented patient was fully withdrawn after only a few days of intravenous rehydration and calcium substitution, followed with thiazide diuretics that reduced urinary loss of calcium. After achieving rapid resolution of symptoms, his treatment continued with oral supplemental calcium and calcitriol preparations for maintenance of serum calcium in the low to normal range.

## Conclusion

Although rare, Fahr's syndrome or/and Fahr's disease are conditions that should be kept in mind in all the cases of progressive neuropsychiatric disturbances and seizure disorders, particularly if they are present in the fourth or fifth decade of age. In such cases, it is especially important to perform laboratory tests for the purpose of prompt registration of possible metabolic abnormalities. Any suspected hypoparathyroidism should be treated in time, especially in subjects that underwent thyroidectomy in order to prevent formation and progression of brain calcifications. On the other hand, every intracranial calcification, incidentally detected during radiographic imaging, needs thorough neurological examination and biochemical tests. Timely recognition of these two entities allows appropriate treatment that can prevent clinical manifestations of the disease and potentially slow its progression.

## R E F E R E N C E S

1. Saleem S, Aslam HM, Anwar M, Anwar S, Saleem M, Saleem A, et al. Fahr's syndrome: Literature review of current evidence. *Orph J Rare Dis* 2013; 8(1): 156.
2. Asokan AG, D'Souza S, Jegathanan J, Pai S. Fahr's Syndrome- An Interesting Case Presentation. *J Clin Diagn Res* 2013; 7(3): 532-3.
3. Kavirayani DK, Jammulapati S. Fahr's syndrome with psychotic features: Review and Case report. *NMJ* 2014; 3(2): 71-4.
4. Kumar S, Sber K, Ahmed S, Naik S, Ayub S, Fatima BM, et al. Fahr's Disease: A Rare Neurological Disease Frequently Misdiagnosed as Acute Psychosis, or Mood Disorder. *J Neurol Disord* 2013; 1: 130.
5. Shoback D. Clinical practice. Hypoparathyroidism. *N Engl J Med* 2008; 359(4): 391-403.
6. Goswami R, Sharma R, Sreenivas V, Gupta N, Ganapathy A, Das S. Prevalence and progression of basal ganglia calcification and its pathogenic mechanism in patients with idiopathic hypoparathyroidism. *Clin Endocrinol (Oxf)* 2012; 77(2): 200-6.
7. Mitchell DM, Regan S, Cooley MR, Lauter KB, Vrla MC, Becker CB, et al. Long-term follow-up of patients with hypoparathyroidism. *J Clin Endocrinol Metab* 2012; 97(12): 4507-14.
8. Caliskan T, Gurbuz S. Fahr's Disease. *J Contemp Med* 2013; 3(2): 133-5.
9. Manyam BV. What is and what is not 'Fahr's disease'. *Parkinsonism Relat Disord* 2005; 11(2): 73-80.
10. Eaton LM, Camp JD, Lore JG. Symmetric cerebral calcification, particularly of basal ganglia, demonstrable roentgenographically; calcification of the finer cerebral blood vessels. *Arch Neurol Psychiatr* 1939; 41: 921-42.
11. Krishnamurthy K, Sonasree J. Fahr's syndrome with psychotic features - Review and Case report. *NMJ* 2014; 3(2): 71-4.
12. Rastogi R, Singh AK, Rastogi UC, Mohan C, Rastogi V. Fahr's syndrome: A rare clinico-radiologic entity. *Med J Armed Forces India* 2011; 67: 159-61.
13. Soares FB, Amorima FF, Santana AR, de Moura EB, Margalho SB, Amorim AP, et al. Fahr's Syndrome due to Hypoparathyroidism Following Thyroidectomy. *J Med Cases* 2013; 4(6): 380-4.
14. Fénelon G, Gray F, Paillard F, Thibierge M, Mabioux F, Guillani A. A prospective study of patients with CT detected pallidal calcifications. *J Neurol Neurosurg Psychiatr* 1993; 56(6): 622-5.
15. Moskowitz MA, Winickoff RN, Heinz ER. Familial calcification of the basal ganglia: A metabolic and genetic study. *N Engl J Med* 1971; 285(2): 72-7.
16. Mufaddel AA, Al-Hassani GA. Familial idiopathic basal ganglia calcification (Fahr's disease). *Neurosciences (Riyadh)* 2014; 19(3): 171-7.
17. Abad MA, Bala CS, Karim SR. Fahr's Syndrome. *Bang Med J (Khulna)* 2012; 45(1-2): 33-5.
18. Rizvi I, Ansari NA, Beg M, Shamim MD. Widespread intracranial calcification, seizures and extrapyramidal manifestations in a case of hypoparathyroidism. *N Am J Med Sci* 2012; 4(8): 369-72.
19. Chowdhury AW, Majumder SN, Amin MG, Islam KN, Saleh MA, Sabah KM, et al. Recurrent Seizure: An Uncommon Presentation of Post Thyroidectomy Hypoparathyroidism. *Bangladesh J Vet Med* 2015; 16(1): 56-8.
20. Zisimopoulou V, Siatouni A, Tsoukalos G, Tavernarakis A, Gatzonis S. Extensive bilateral intracranial calcifications: A case of iatrogenic hypoparathyroidism. *Case Rep Med* 2013; 2013: 932184.
21. Castro MC, Singer BH. Agricultural settlement and soil quality in the Brazilian Amazon. *Popul Environ* 2012; 34(1): 22-43.
22. Ghosh K, Sengupta N, Sau TJ, Chatterjee A. Rare presentation of a common disease: Idiopathic hypoparathyroidism presenting with extrapyramidal symptoms and status epilepticus. *Indian J Endocr Metab* 2012; 16(6): 1035-6.
23. Panduranga P, Sulaiman K. Is there an association between Fahr's disease and cardiac conduction system disease?: A case report. *J Res Med Sci* 2012; 17(1): 96-100.
24. Winer KK, Zhang B, Shrader JA, Peterson D, Smith M, Albert PS, et al. Synthetic human parathyroid hormone 1-34 replacement therapy: a randomized crossover trial comparing pump versus injections in the treatment of chronic hypoparathyroidism. *J Clin Endocrinol Metab* 2012; 97(2): 391-9.
25. Winer KK, Cutler GB. Treatment of Hypoparathyroidism with Parathyroid Hormone 1-34. In: Brandi ML, Brown EM, editors. *Hypoparathyroidism*. Milano: Springer-Verlag Italia; 2015. p. 319-31.

Received on September 16, 2015.

Revised on October 26, 2015.

Accepted on November 3, 2015.

Online First May, 2016.